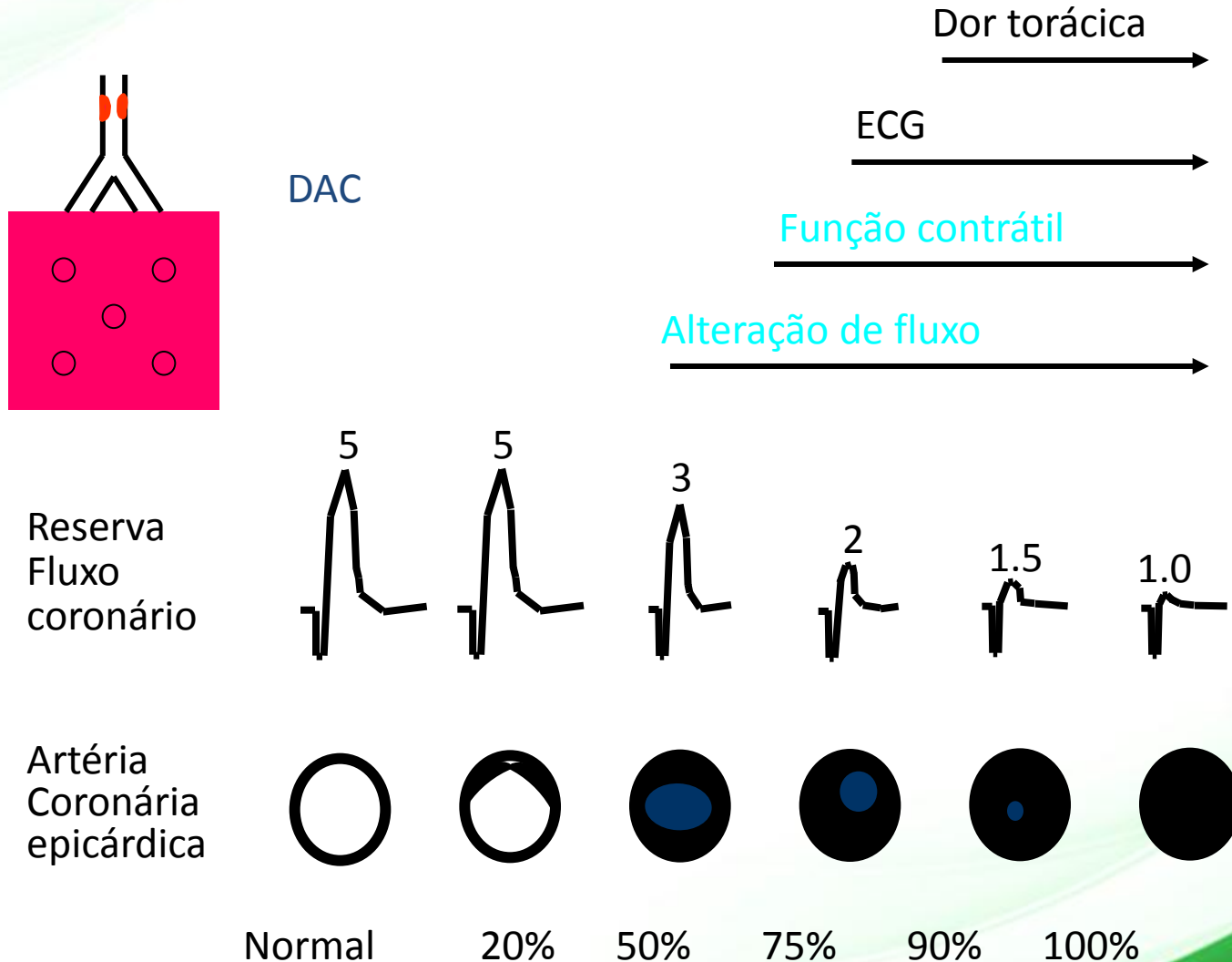


Ecocardiografia na Doença Arterial Coronariana

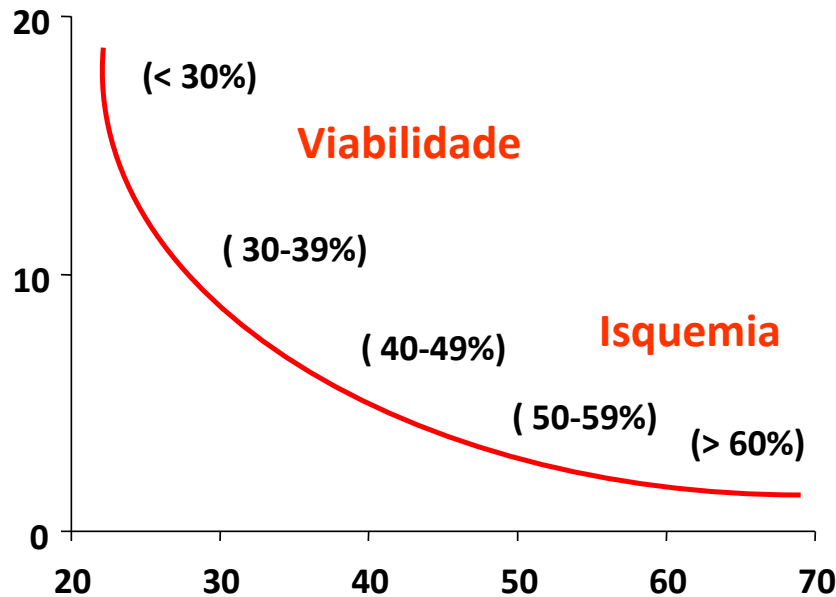
Dr. Marcelo Paiva



Interpretação dos sinais de isquemia



Função Ventricular Esquerda

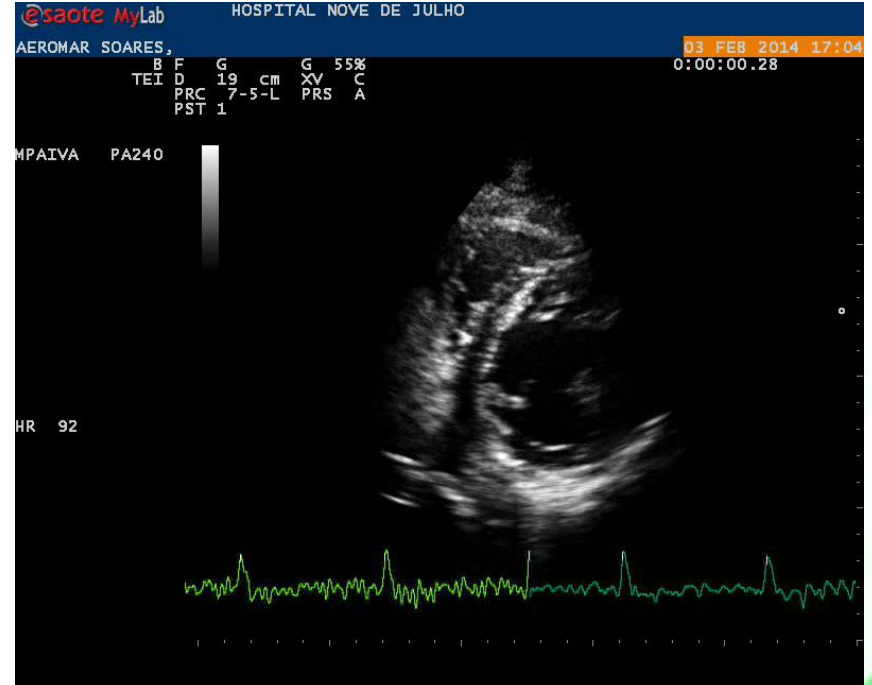
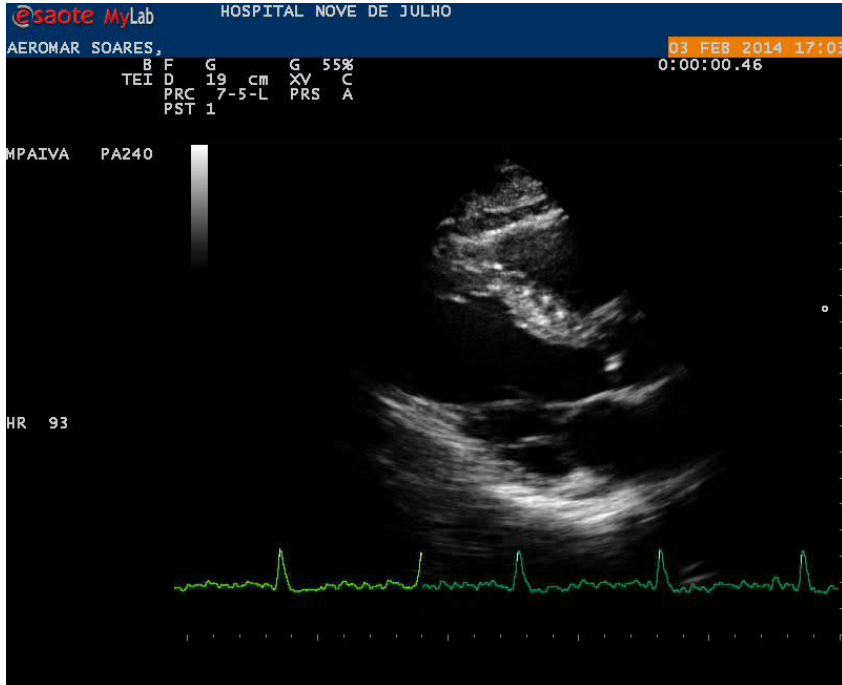


FEVE	Mortalidade%
< 30	15,2
30 - 39	8,6
40 - 49	2,2
50 - 59	1,3
> 60	1,1

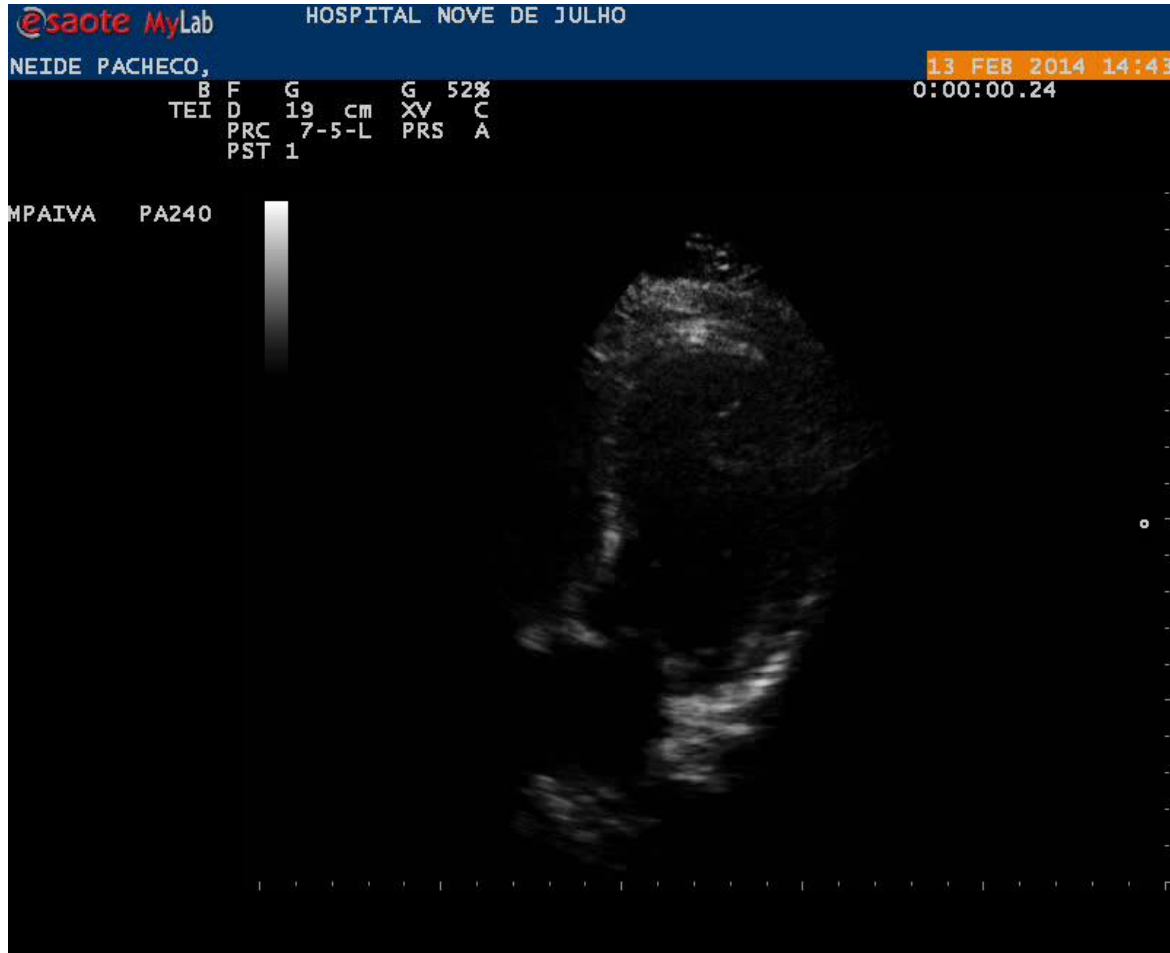Gissi II Trial Data Base, Circulation. v. 88: p. 416-429, 1993.



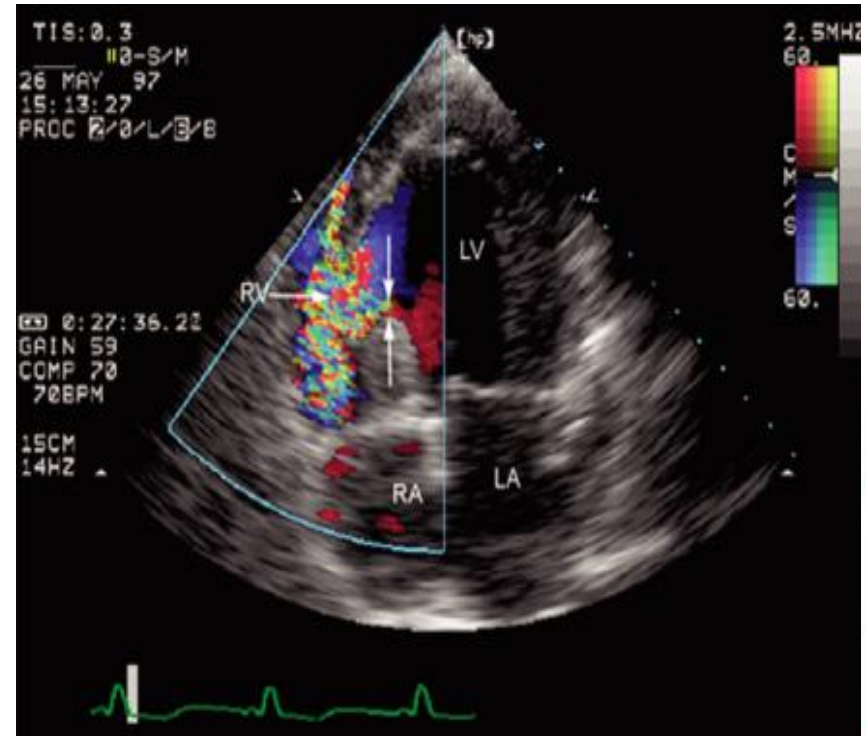
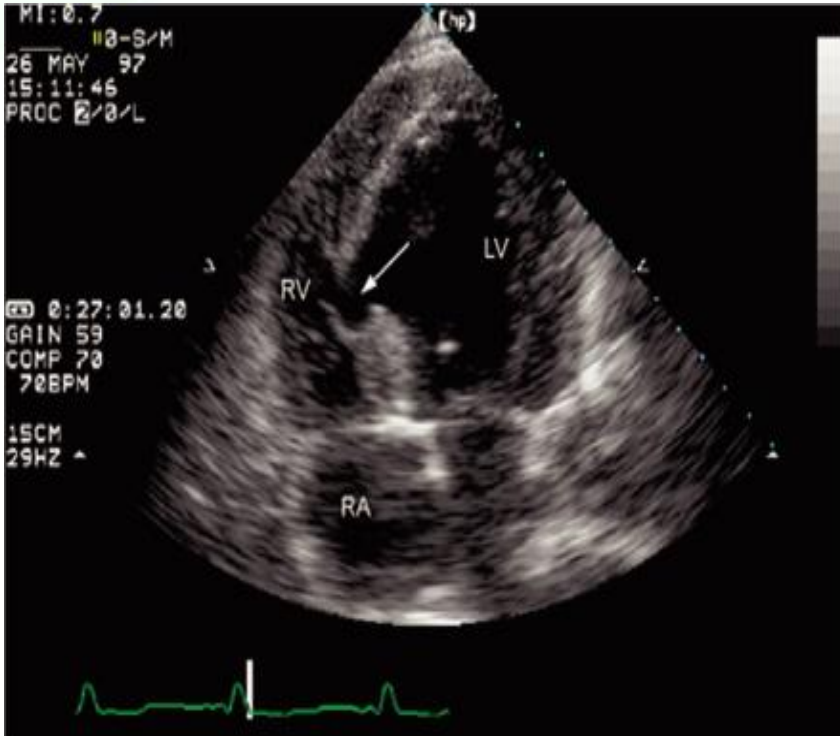
Ecocardiograma na SCA



Complicações

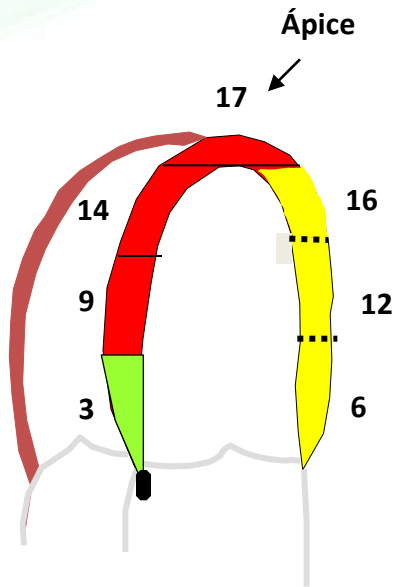


Complicações

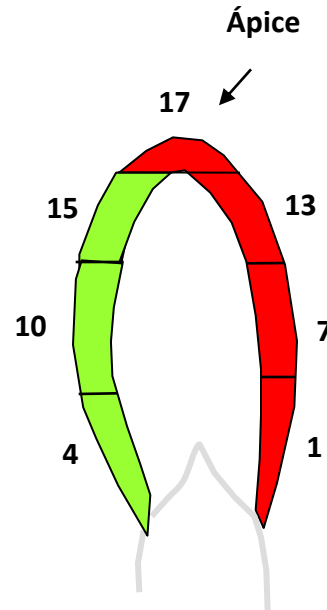


Métodos

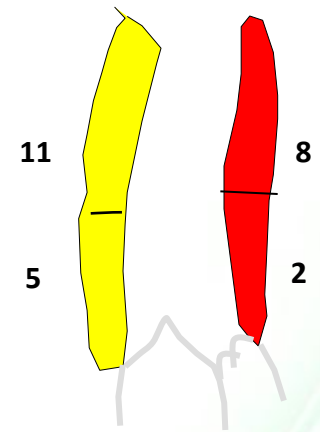
Divisão do VE em 17 Segmentos



Eixo longo horizontal
(4 câmaras)



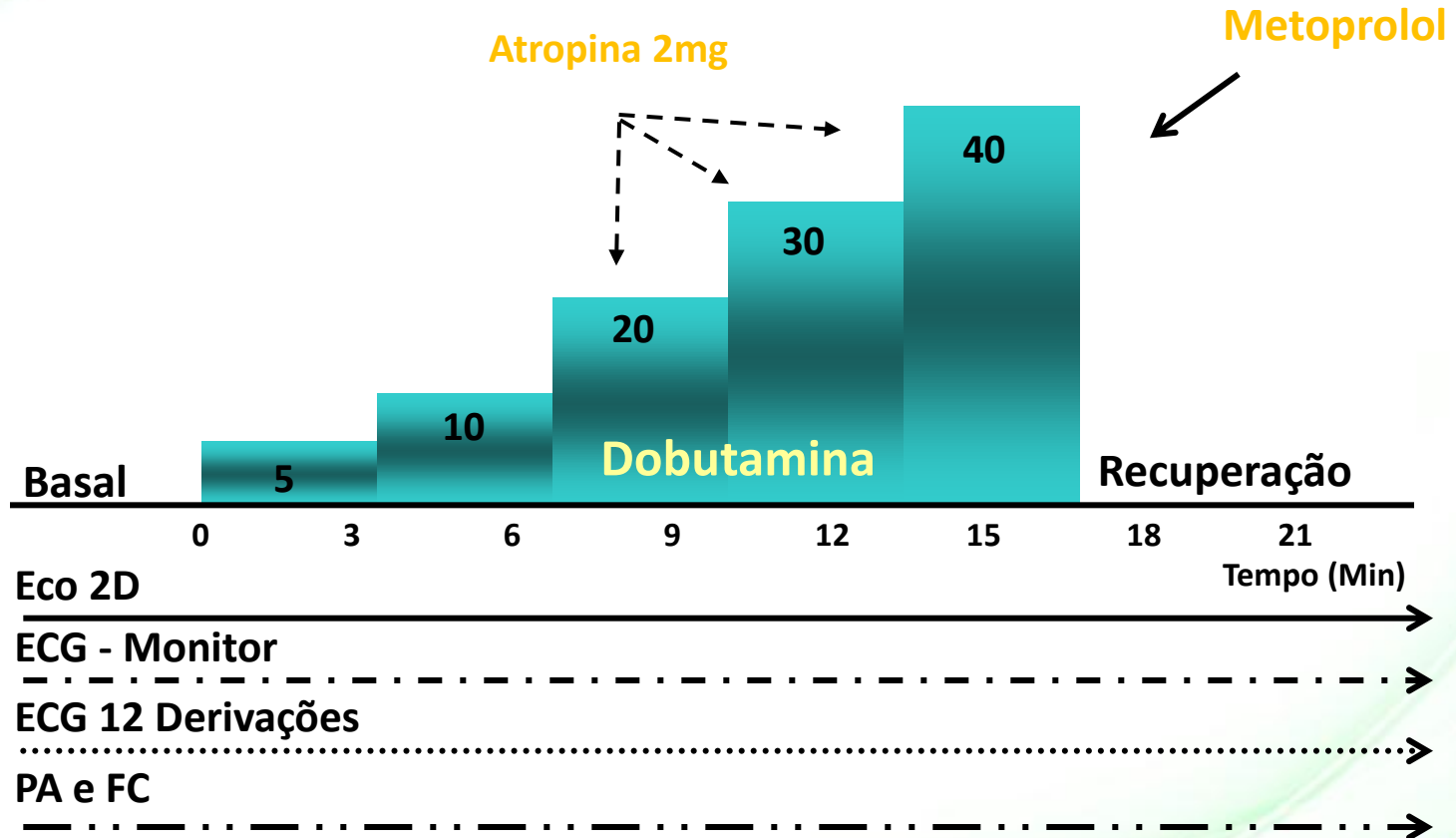
Eixo longo vertical
(2 câmaras)



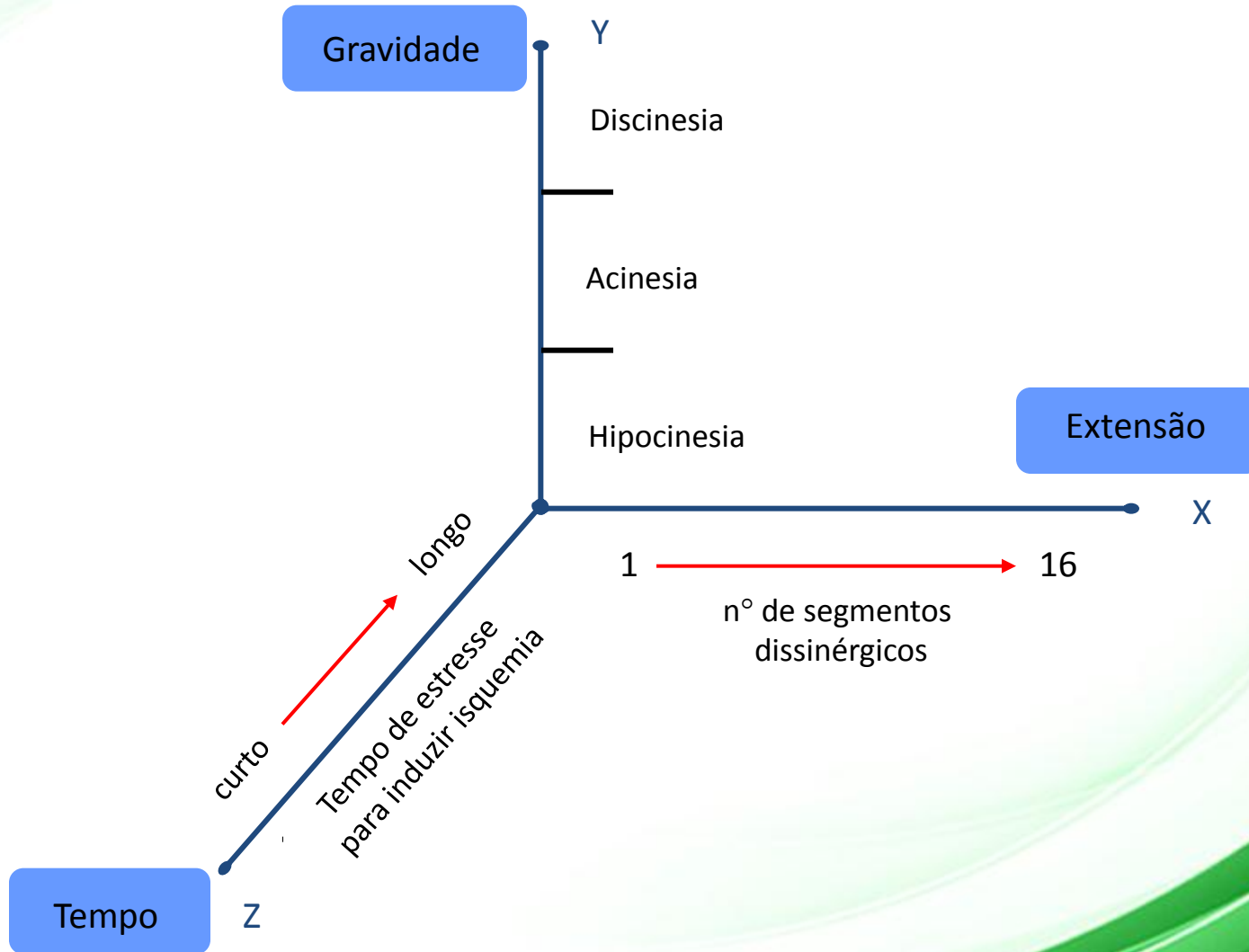
Eixo longitudinal
(3 câmaras)

■ ADA ■ CD ■ CX

Ecocardiografia Sob Estresse pela Dobutamina



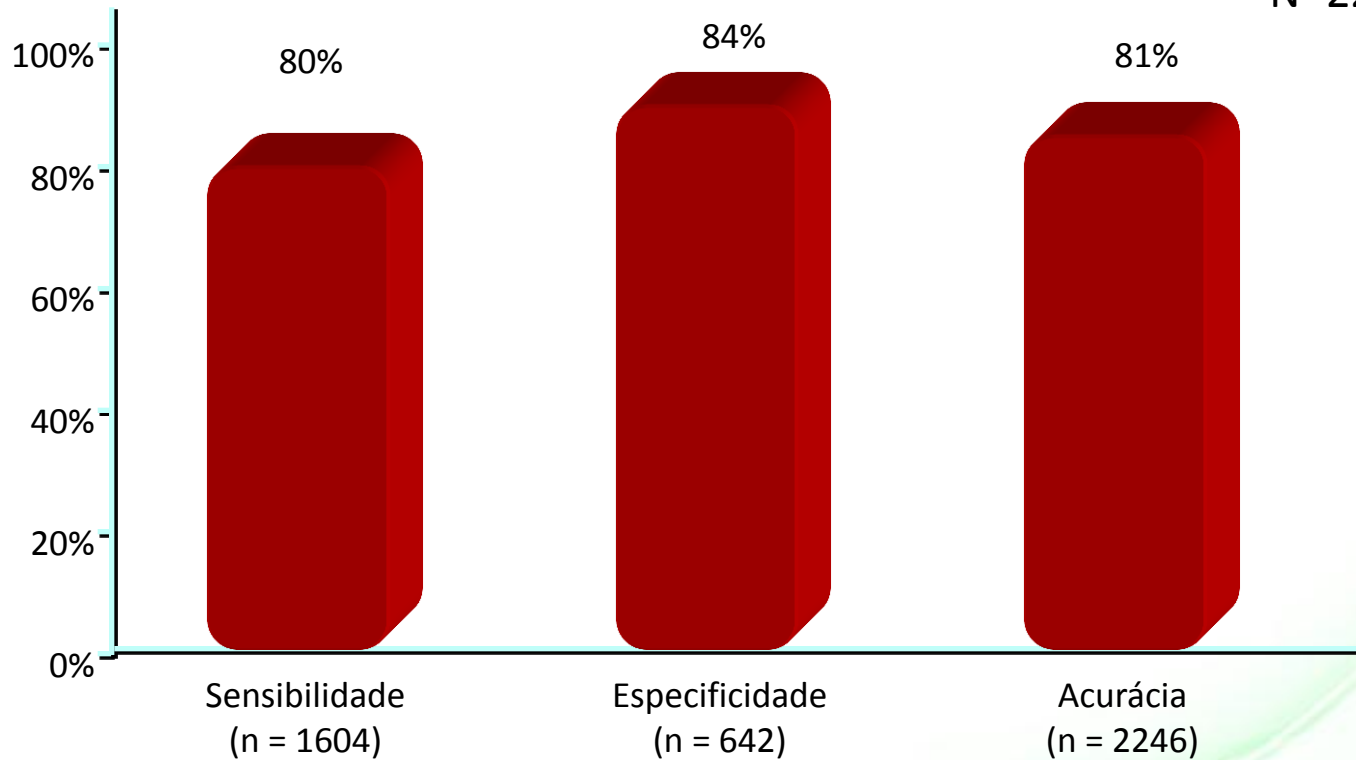
Estratificação da resposta isquêmica



Ecocardiografia sob Estresse

Acurácia total - Metanálise

28 estudos
N- 2246 pt

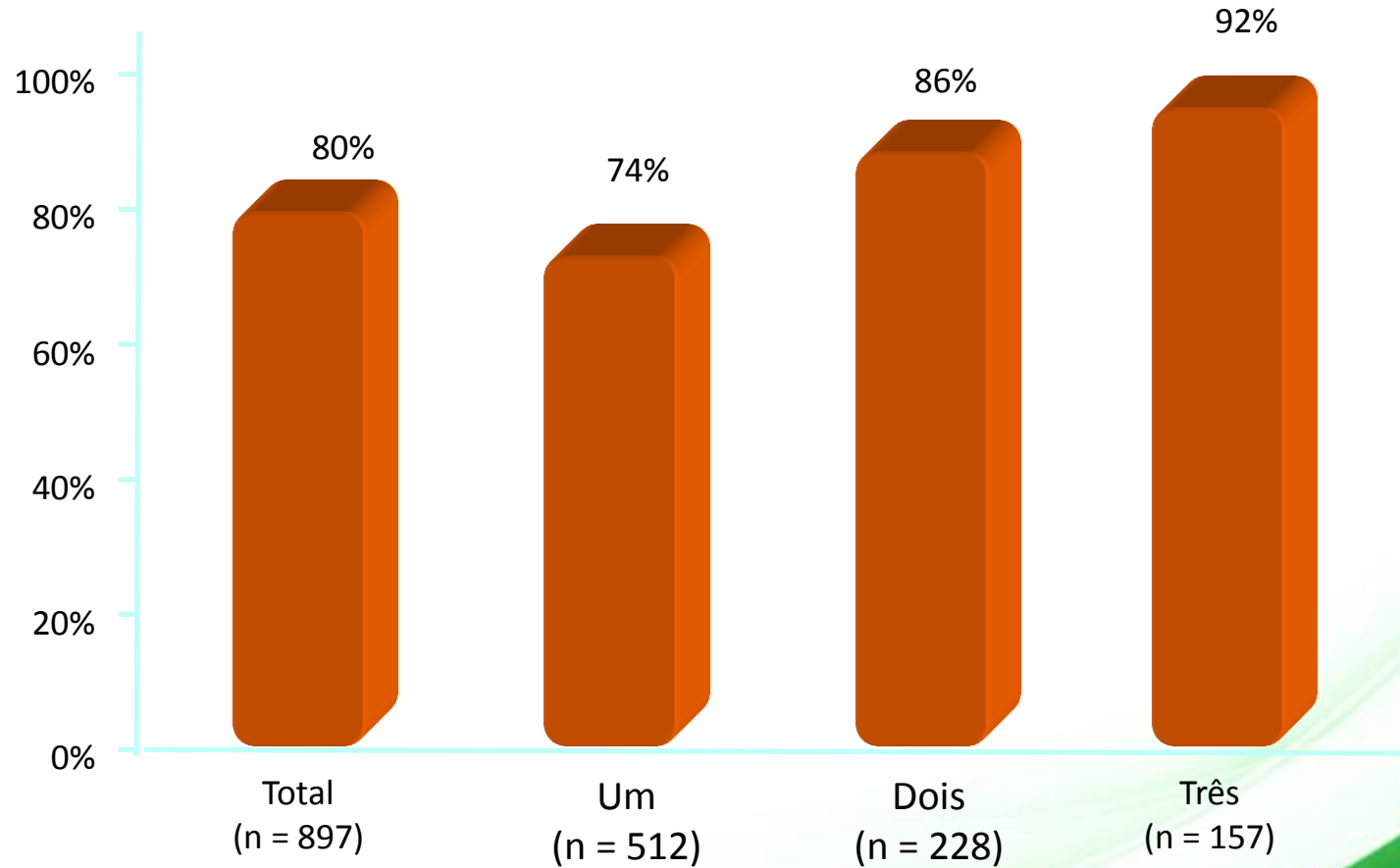


REG 1097520100005-606

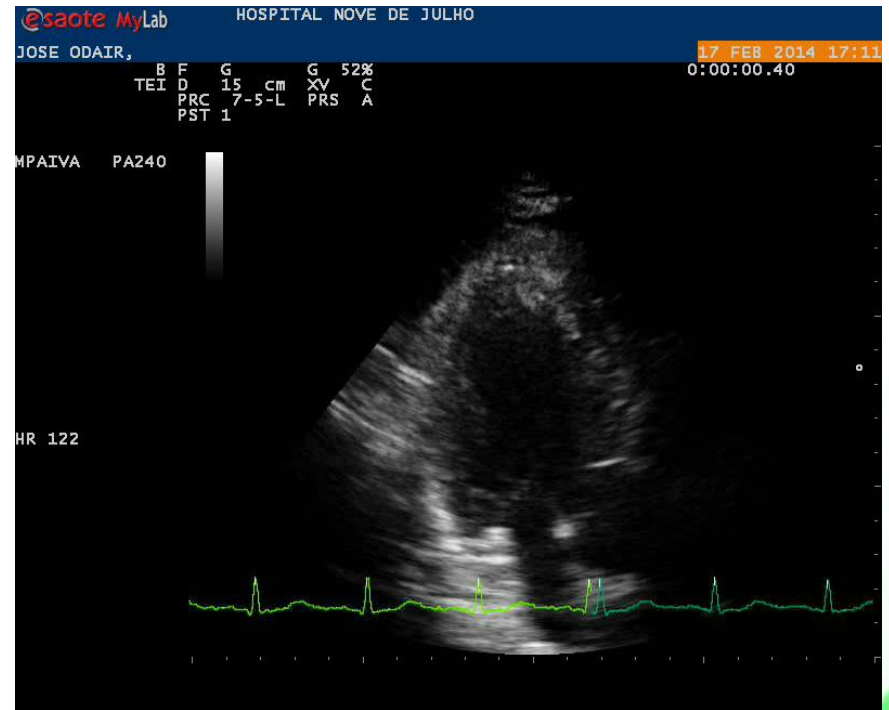
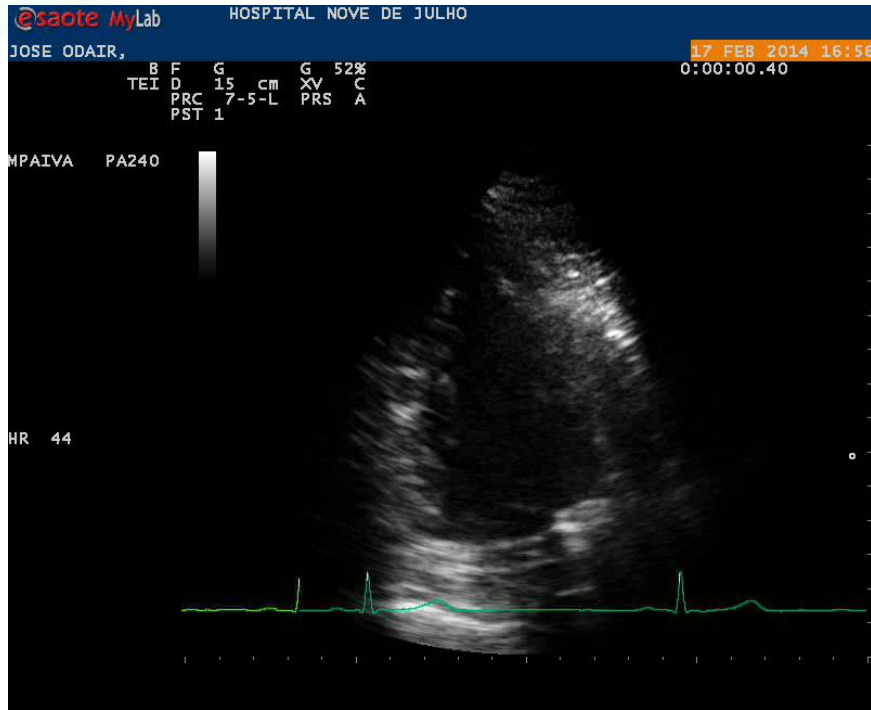


Ecocardiografia sob Estresse

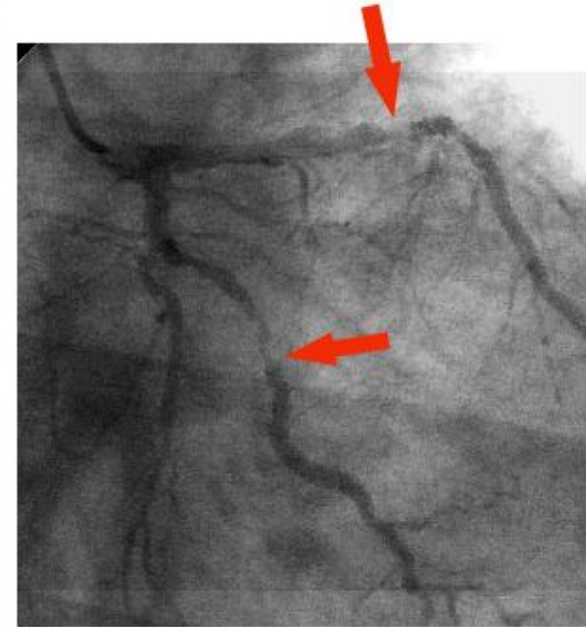
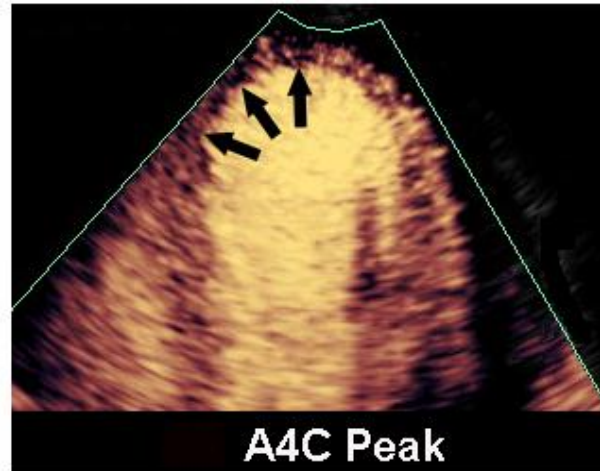
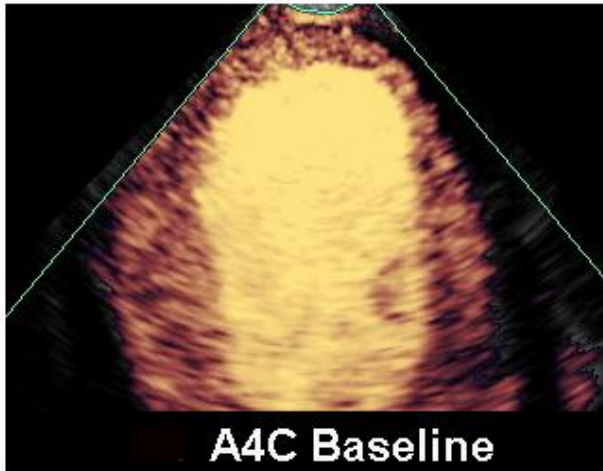
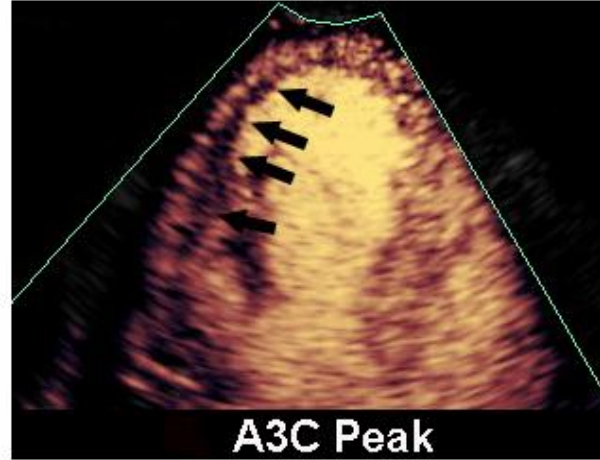
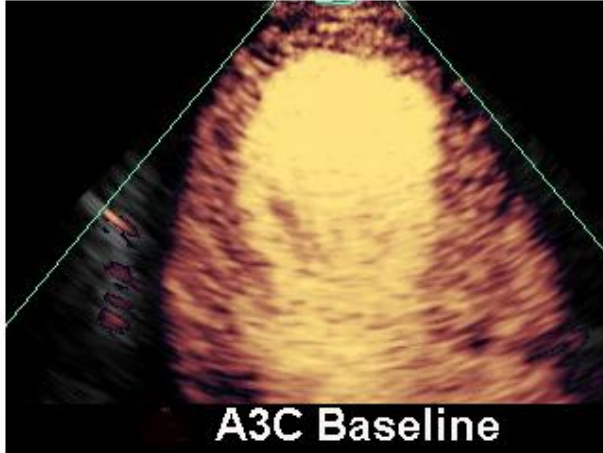
Acurácia total – Número de vasos envolvidos



Ecocardiograma de Estresse Farmacológico



Eco com contraste



Prognóstico

Qual teste usar para cada paciente ?

